

## Eisenmerger Syndrome: Clinical Images

Ijeoma Arodiwe\*

Department of Paediatrics, University of Nigeria/Teaching Hospital, Enugu, Nigeria

\*Corresponding author: Ijeoma Arodiwe, Department of Paediatrics, University of Nigeria/Teaching Hospital, Enugu, Nigeria, Tel: +234 803 722 1864; E-mail: ijeoma.arodiwe@unn.edu.ng

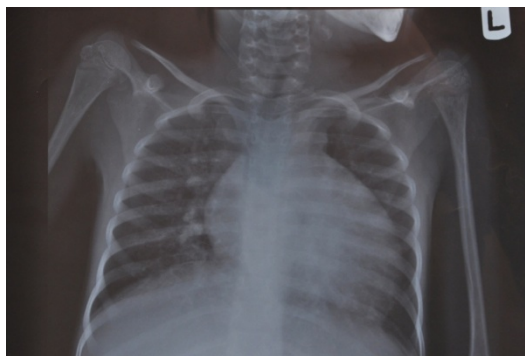Received date: July 01, 2017; Accepted date: July 03, 2017; Published date: July 07, 2017

Citation: Ijeoma Arodiwe (2017) Eisenmerger Syndrome: Clinical Images. Pediatric Infect Dis Vol. 2 No.3: 47.

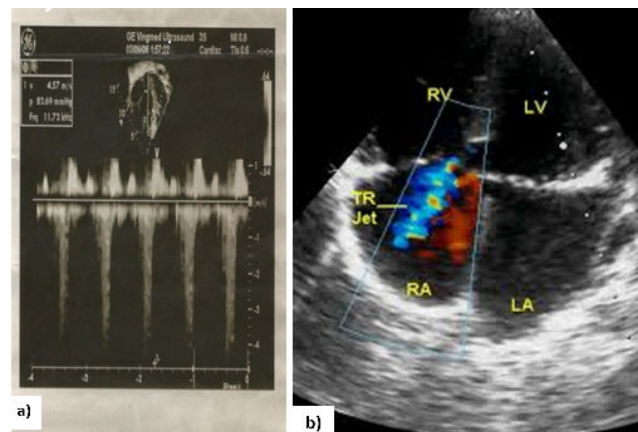
Copyright: © 2017 Arodiwe I. This is an open-access article distributed under the terms of the Creative Commons Attribution License, which permits unrestricted use, distribution, and reproduction in any medium, provided the original author and source are credited.

### Clinical Image

OO, is a 9 year old girl who presented with progressive easy fatigability, fast breathing and intermittent cough since early infancy. She was being managed for Patent ductus arteriosus, but defaulted for 4 years. At representation, in addition to the above, she developed bluish discoloration of the lips and mucosa (Figures 1 and 2) [1-3].



**Figure 1:** CXR-Cardiomegaly with a CTR of 80% Oligemic field.



**Figure 2:** (a, b) 2D Echo-Large 7.2 mm PDA shunting right to left with gross chambers dilation and Severe Tricuspid Regurgitation  $pg=85$  mmHg.

### References

1. Young D, Mark H (1971) Fate of the patient with the Eisenmenger syndrome. *Am J Cardiol* 28: 658-669.
2. Engelfriet PM, Duffels MG, Moller T (2007) Pulmonary arterial hypertension in adults born with a heart septal defect: the Euro Heart Survey on adult congenital heart disease. *Heart* 93: 682-687.
3. Wood P (1958) The Eisenmenger syndrome or pulmonary hypertension with reversed central shunt. *I Br Med J* 2: 701-709.